

Dentigerous cyst : A Case report

Salma Albat1st, Tarek Kasem 2nd, Jihad Alokaily 3rd

Abstract— Dentigerous cyst (DC) is one of the most common type of odontogenic cyst, developed abnormally around unerupted teeth. DC is frequently found in the age group between 20 and 40 years. Small dentigerous cysts are asymptomatic and discovered only on routine radiographic examination. A case of a 12 year old boy with a symptomatic dentigerous cyst in the right mandibular premolar region was studied. The management comprised of enucleation and one year follow up.

Index Terms—Dentigerous cyst, Syrgical enucleation, Oral cyst, Inflammatory cyst.

INTRODUCTION

Dentigerous cysts are commonly found associated with an unerupted tooth, developing tooth bud. It is most frequently associated with the crowns of mandibular third molars followed by maxillary canines and then maxillary molars.¹

Benn and Altini suggested that periapical inflammation from a non vital tooth may spread to involve the follicle of the permanent successor. The inflammatory exudate leads to the formation of a dentigerous cyst.² The treatment of choice in dentigerous cyst is enucleation and extraction of the associated tooth.

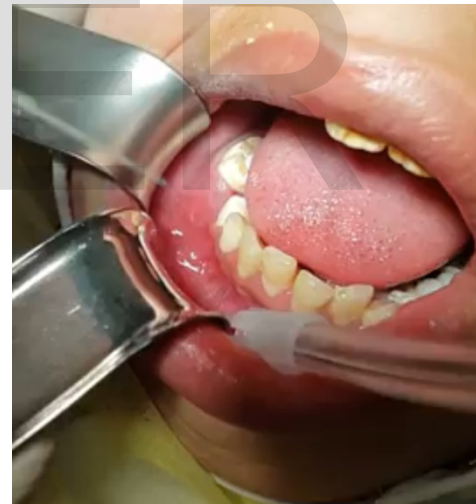CASE REPORT

A 12 year old boy was referred to the department of oral and maxillofacial surgery, AlRass general hospital, Qassim with a complaint of a painful swelling in the right mandibular posterior region with no significant medical history.

Clinical examination revealed an extra oral swelling in the lower third of right side of his face. Intra oral examination revealed a swelling extending from right mandibular permanent first premolar to right mandibular permanent first molar (Fig 1). A thorough dental examination revealed a large temporary restoration on his right mandibular deciduous second molar. Pulp vitality tests indicated that the right mandibular permanent first molar was non vital.

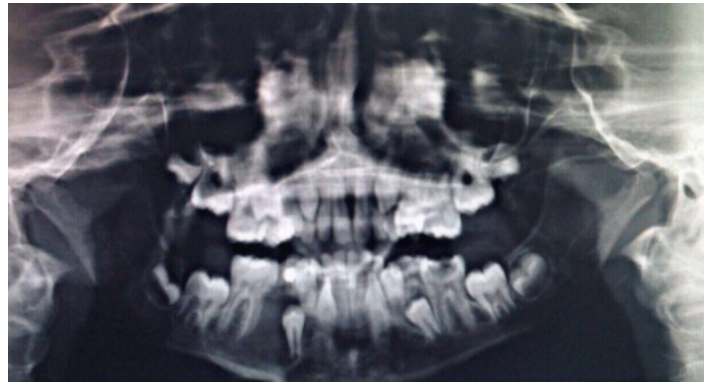
Panoramic radiograph revealed a large well defined unilocular radiolucency with corticated margins in the periapical region of the right mandibular permanent first molar (Fig 2). The unilocular swelling was enveloping the unerupted mandibular right permanent second premolar with the attachment being at the cervical margin of the premolar. On aspiration few drops of blood mixed fluid was obtained. Surgical enucleation procedure was carried out with extraction of the involved tooth under local anaesthesia (Figures 3,4,5A&B). The

excised specimen was sent for routine histopathological examination. On microscopic examination the lesion was diagnosed as dentigerous cyst (Fig 6). Radiographs were made at follow up intervals of 4 month interval (Fig 7) and at the end of one year (Fig 8). The one year post operative radiograph showed the healed surgical margins following enucleation of the margins.

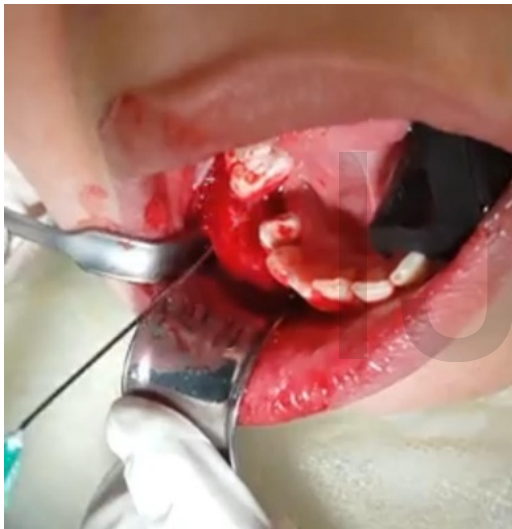

(Fig1) Clinical photo shows a swelling extending

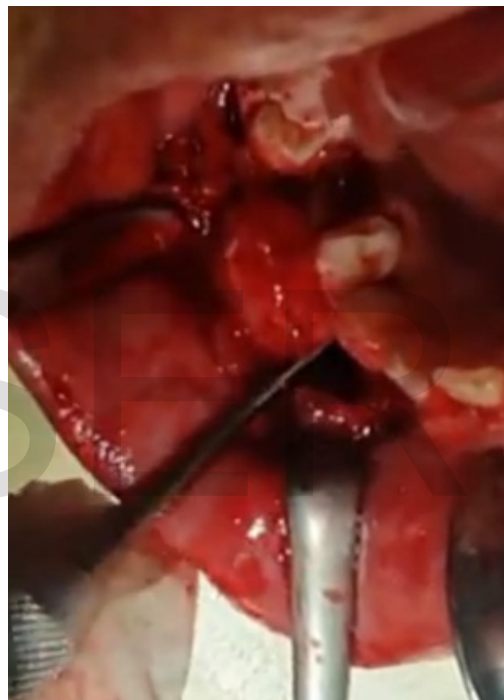from right mandibular permanent first premolar to right mandibular permanent first molar.



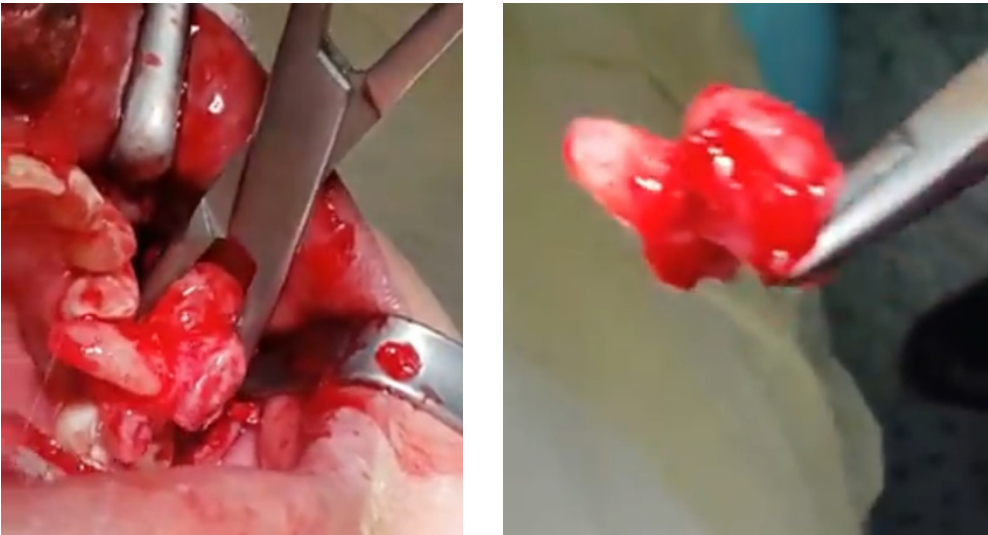(Fig2) OPG revealed a large well defined unilocular radiolucency with corticated margins in the periapical region of the right mandibular permanent first molar



(FIG 3)



(FIG 4)



(Fig 5A & 5B)

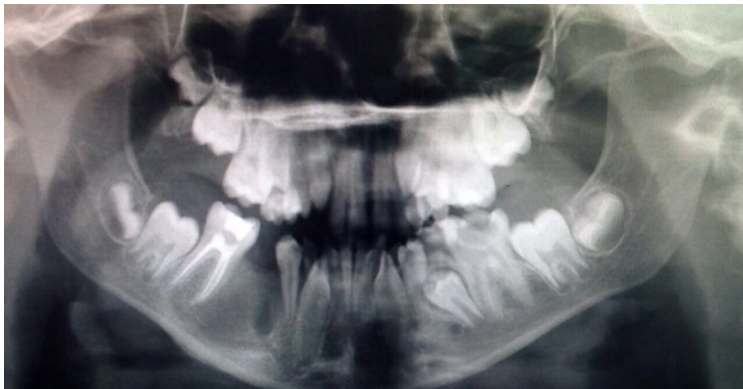Histopath No.: RGH-37-1151	Date Received: 25/06/1437
Name: [REDACTED]	File No.: [REDACTED]
Age: 12 Sex: Male	Nationality: Saudi
Ward/Clinic: Dental	Referring Doctor: Dr. Tarik Kasem
Site/Nature of Specimen: Mandible soft tissue	Clinical Diagnosis: Dentigerous cyst??

GROSS DESCRIPTION:
Specimen consists of two irregular pieces weighing 5 grams containing 1 teeth, largest measuring 2x2 cm wall thickness 0.5cm, smallest measuring 1.5x1.5cm

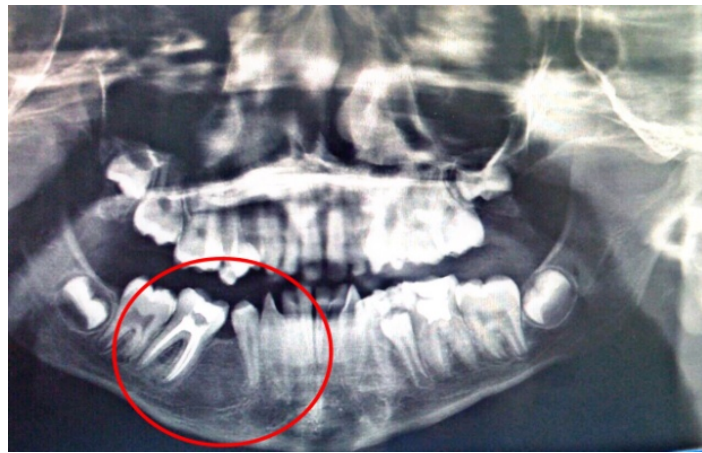MICROSCOPIC DESCRIPTION:
Microscopic examination of sections of specimen received showed picture compatible with inflamed dentigerous cyst.

DIAGNOSIS:
MANDIBULAR LESION; PICTURE COMPATIBLE WITH INFLAMED DENTIGEROUS CYST.
FOR CLINICAL AND RADIOLOGICAL CORRELATION

(Fig 6)



(Fig 7)



(Fig 8)

DISCUSSION

Dentigerous cysts are defined as a cystic cavity originated from the accumulation of fluid between the reduced enamel epithelium and the crown of an unerupted tooth, attached to the cemento-enamel junction.⁴

DC is the second most common odontogenic cyst. It presents mostly in the second or third decade of life in the maxillary and mandibular third molar or maxillary canine region. Although most dentigerous cysts are considered developmental in origin, some cysts appear to have an inflammatory pathogenesis. Occasionally dentigerous cyst may develop around the crown of an unerupted/developing permanent tooth as a result of periapical inflammation from an overlying primary tooth. Another scenario involves a partially erupted mandibular third molar that develops an inflamed cyst like lesion along the distal or buccal aspect.

Radiographic presentation may be unilocular radiolucent cysts of varying size. The present case the cyst had an unilocular radiolucency. The differential diagnosis of DC includes keratocystic odontogenic tumor (KCOT), adenomatoid odontogenic tumor, (AOT) calcifying epithelial odontogenic tumor (CEOT), and unicystic ameloblastoma.⁵

Bilateral and multiple cysts have been reported in patients with syndromes such as basal cell nevus syndrome, mucopolysaccharidosis and cleidocranial dysplasia.⁶

The present case revealed a circumferential variety of dentigerous cyst with reference to the cyst-to-crown relationship. The cyst growth in this case was quite extensive.

Histopathologically, the supporting fibrous connective tissue wall of the cyst is lined by stratified squamous epithelium.

Treatment of DC depends on location, size, disfigurement and often requires variable bone removal to ensure the total removal of cyst.⁷ The present case was treated by surgical enucleation procedure with extraction of the involved tooth. A one year follow up revealed normal bone formation in the enucleated area.

4 SUMMARY & CONCLUSION

Early diagnosis with clinical and radiographic investigations are important while treating cysts of the oral cavity. Histopathological examination of cyst linings should be done to rule out any changes in the cyst lining. Enucleation without leaving any lesional tissue should be the treatment of choice in case of dentigerous cysts.

REFERENCES

- [1] Salzar M, Sellos MC, Americano GCA, da Costa MO, de Marsillac MVS, Campos V. Dentigerous cyst involving permanent incisor. A case Report. *SM Dent Oral Disord*.2017 ;1(1);1002
- [2] Benn A, Altini M. Dentigerous cysts of inflammatory origin. *Aclinicopathologicstufy. Oral Surg Oral Med Oral Pathol Oral Radiol Endod*.1996 Feb 81(2);203-209.
- [3] Anderson DW, Evans D. Dentigerous cyst of mandible presenting as sepsis. *Am J Emerg Med* 2014;32;1561.e3-4
- [4] Regexi J. A Scuba J. *Oral Pathology: Clinical pathologic correlations*. 2nd Ed. Philedelphia WB Saunders,1993;326-332.
- [5] Shafer W G, Hine m.k, Levy B.M. *A text book of oral pathology* 4th ed. Philadelphia; WB Saunders 1983;260-265.
- [6] Gorlin RJ. Cysts of the jaws, Oral floor and neck. In: Gorlin RJ, Goodman hw, EDITORS. *Thoma's Oral Pathology*, 6th ed. Vol. 1 St.Louis. Mosby;1970.
- [7] Ko KS, Dover DG, Jordan RC. Bilateral dentigerous cysts: Report of an unusual case and review of the literature. *J Can Dent Assoc* 1999;65(1):49-51.

IJSER